

Semantic Knowledge in Patient H.M. and Other Patients With Bilateral Medial and Lateral Temporal Lobe Lesions

Heike Schmolck,² Elizabeth A. Kensinger,⁵
Suzanne Corkin,⁵ and Larry R. Squire^{1,2,3,4*}

¹Veterans Affairs Medical Center, San Diego, California

²Department of Psychiatry, University of California, La Jolla, California

³Department of Neurosciences, University of California, La Jolla, California

⁴Department of Psychology, University of California, La Jolla, California

⁵Department of Brain and Cognitive Sciences and the Clinical Research Center, Massachusetts Institute of Technology, Cambridge, Massachusetts

ABSTRACT: We investigated the effects of damage to the medial temporal lobe (MTL) and anterolateral temporal cortex on semantic knowledge. We studied eight male controls, two patients with lesions limited to the hippocampal formation, three postencephalitic patients with extensive MTL lesions and variable damage to the lateral temporal cortex, and patient H.M. (whose lesion is limited mostly to the MTL, but who also has minimal damage to the anterolateral cortex). On 13 tests of semantic memory, patients with lesions limited to the hippocampal formation performed similarly to controls. Postencephalitic patients were mildly to moderately impaired on most tests. Patient H.M.'s performance was impaired on only a few tests and was less severely impaired overall than the three postencephalitic patients. A ranking of test scores showed a direct relationship between impairment and the extent of damage to lateral temporal cortex. These findings, and related findings from other studies, point to the importance of anterolateral temporal cortex for semantic knowledge. Patient H.M. performed uniquely in certain respects. For example, when providing definitions of objects, he made many grammatical errors. In contrast, the other patients with large MTL lesions made no more errors than those made by controls. Considering that H.M.'s lesion, both medially and laterally, is less extensive than the lesions in these other patients, it appears unlikely that his shortcomings in language production are related to his temporal lobe lesion. *Hippocampus* 2002;12:520–533. Published 2002 Wiley-Liss, Inc.†

KEY WORDS: memory; hippocampus; perirhinal cortex; parahippocampal cortex

Grant sponsor—Medical Research Service of the Department of Veterans Affairs; Grant sponsor—National Institute of Mental Health; Grant number—24600; Grant sponsor: Metropolitan Life Foundation; Grant sponsor: DFG; Grant number: Vo 770/1-1.

*Correspondence to: Larry Squire, Department of Psychiatry 0603, University of California, La Jolla, CA 92093.

E-mail: lsquire@ucsd.edu

Accepted for publication 5 November 2001

DOI 10.1002/hipo.10039

INTRODUCTION

Bilateral medial temporal lobe lesions cause severe and lasting memory impairment, affecting the ability both to acquire new information and to recall information learned previously (Scoville and Milner, 1957; Corkin, 1984; Stefanacci et al., 2000; Manns and Squire, in press). At the same time, information acquired early in life is spared. For example, amnesic patient H.M. exhibits intact grammatical processing and intact lexical information, such as intact information about words and word forms (Kensinger et al., 2001). He also has preserved intellectual ability, as indicated by stable performance on four subtests of standard intelligence tests, which were administered preoperatively and then on multiple occasions across five decades (Kensinger et al., 2001). Another amnesic patient (E.P.) exhibited intact memory for the spatial layout of the neighborhood where he grew up but moved away from as a young adult (Teng and Squire, 1999). Such findings provide support for the view that medial temporal lobe structures are required for the acquisition of new knowledge, but not for the retrieval and use of remote, well-established semantic knowledge.

In contrast to these findings of preserved cognitive abilities other than memory, it was recently reported that H.M., E.P., and other patients with large medial temporal lobe lesions were impaired at detecting and explaining ambiguity in sentences (MacKay et al., 1998b; Schmolck et al., 2001; Squire et al., 2001). It is unclear how exceptional this impairment is and whether it might be part of a broader impairment in semantic knowledge. The anatomical basis of the impairment is also unclear. The pa-

tients who were tested and found to be impaired did have medial temporal lobe lesions, but all the patients, including H.M., also have at least some damage to lateral temporal cortex. Accordingly, impaired appreciation of sentence ambiguity could be the result of lateral temporal damage. It was also of interest that H.M. had deficits on this task that were not present in any of the other patients with large medial temporal lobe lesions (Schmolck et al., 2000), raising the possibility that some of H.M.'s difficulties might be unrelated to his lesion.

In the present study, we gave a large series of semantic knowledge tests to patients with medial temporal lobe lesions and variable damage to lateral temporal cortex (the same patients tested previously). In addition, we tested patients with lesions restricted to the hippocampal formation within the medial temporal lobe. Finally, we tested H.M. and compared his performance with that of the other patients. The purpose of the study was twofold: first, to assess the relation between test performance and the extent of damage to lateral temporal cortex and second, to determine whether any aspects of H.M.'s performance were unique among the patients tested.

METHODS

Participants

We studied three patients who developed amnesia after herpes simplex encephalitis (E.P., G.P., and G.T.). These patients have large medial temporal lobe lesions, as well as variable damage to anterolateral temporal cortex (MTL+) (Fig. 1). We also studied patient H.M., who underwent bilateral medial temporal lobe resection for relief of severe epilepsy (Scoville and Milner, 1957). Other participants included two amnesic patients with damage believed to be limited to the hippocampal formation (HF) and eight controls (CON) (Table 1). Magnetic resonance images (MRI) of the patients with MTL+ lesions, and one of the two patients with HF lesions, were acquired in a 1.5-tesla (T) Signa Clinical scanner at the UCSD Medical Center. Descriptions of the lesions are based on axial T2-weighted, proton density fast spin-echo (FSE) images through the brain, matrix = 256×256 , field of view (FOV) = 20–22 cm (0.78–0.86 mm in-plane resolution), 5-mm-thick sections; and on coronal oblique, T1-weighted images perpendicular to the long axis of the hippocampus, matrix = 256×256 , FOV = 16–20 cm (0.63–0.78 mm in-plane resolution), 5-mm-thick, interleaved sections.

Patients with medial temporal lobe lesions and variable damage to anterolateral temporal cortex (MTL+)

Patient E.P. E.P. developed profound amnesia in 1992 after herpes simplex encephalitis. His lesion is primarily medial temporal but also compromises the anterior portion of the fusiform gyrus. The damage extends 7 cm caudally from the temporal pole bilaterally, and includes all of the amygdala and all of the hip-

pocampal region (dentate gyrus, cell fields of the hippocampus proper, and subicular complex except for a small tag of abnormally appearing vestigial tissue on each side that comprises about 10% of hippocampal volume). In addition, the damage includes all of the entorhinal cortex, all of the perirhinal cortex, and much of the parahippocampal cortex (about 20% on the left and 60% on the right). Estimates of damage for the patients are based on quantitative analysis, following published procedures for segmenting the temporal lobe (Insausti et al., 1998; Amaral and Insausti, 1990). The lesion also extends laterally to include the rostral portion of the fusiform gyrus (40% damage on the left, 53% on the right). The lateral temporal cortex (inferior, middle, and superior temporal gyri) is reduced in volume bilaterally, particularly on the right side (left side = 10%; right side = 25%). The insula is also reduced in size bilaterally, with more substantial loss on the left side (19%) than on the right (11%) (Stefanacci et al., 2000).

Patient G.P. G.P. developed profound amnesia in 1987 after herpes simplex encephalitis. Like E.P., G.P.'s damage is primarily medial temporal, but his lesion extends further laterally. The damage extends through the anterior 7 cm of the left temporal lobe and the anterior 6 cm of the right temporal lobe. The damage includes bilaterally all of the amygdala, all of the hippocampal region, all of the entorhinal and perirhinal cortices, and much of the parahippocampal cortex (77% on the left and 17% on the right). Lateral damage is most severe in the anterior 1 cm of the temporal lobe, where it includes the fusiform gyrus as well as the inferior, middle, and superior temporal gyri, bilaterally. From 1 cm to 4.5 cm caudally, the lateral damage is restricted to the fusiform gyrus and the inferior temporal gyrus. The insular cortex is also damaged, with the lesion extending caudally on the left side (3 cm) more than on the right side (2.5 cm) (Schmolck et al., 2000; Fig. 2).

Patient G.T. G.T. developed profound amnesia in 1990 after herpes simplex encephalitis. His lesion extends laterally to include most of the temporal lobes bilaterally. The damage compromises the anterior 7 cm of the left temporal lobe, and the anterior 5 cm of the right temporal lobe, including bilaterally all of the amygdala, all of the hippocampal region, all of the entorhinal and perirhinal cortices, and much of the parahippocampal cortex (100% on the left and about 43% on the right). Lateral cortical regions (fusiform gyrus; inferior, middle, and superior temporal gyri) are also damaged bilaterally at the level of the temporal pole. The damage to the fusiform gyrus continues caudally from the temporal pole for 6.0 cm on the left and for 4.5 cm on the right. The damage to the inferior, middle, and superior temporal gyri extends caudally from the temporal pole for 4.5 cm on the left and 2.5 cm on the right. There is also bilateral insular damage, more extensive on the left than on the right (Schmolck et al., 2000; Fig. 3).

Patient H.M. The well-studied patient H.M. (Scoville and Milner, 1957; Corkin, 1984) has bilateral damage that is largely restricted to the medial temporal lobe. Within the medial temporal lobe, he has some sparing of the ventrocaudal aspect of the perirhinal cortex, and almost complete sparing of the parahippocampal cortex. In addition, the posterior portion of the hippocampal for-

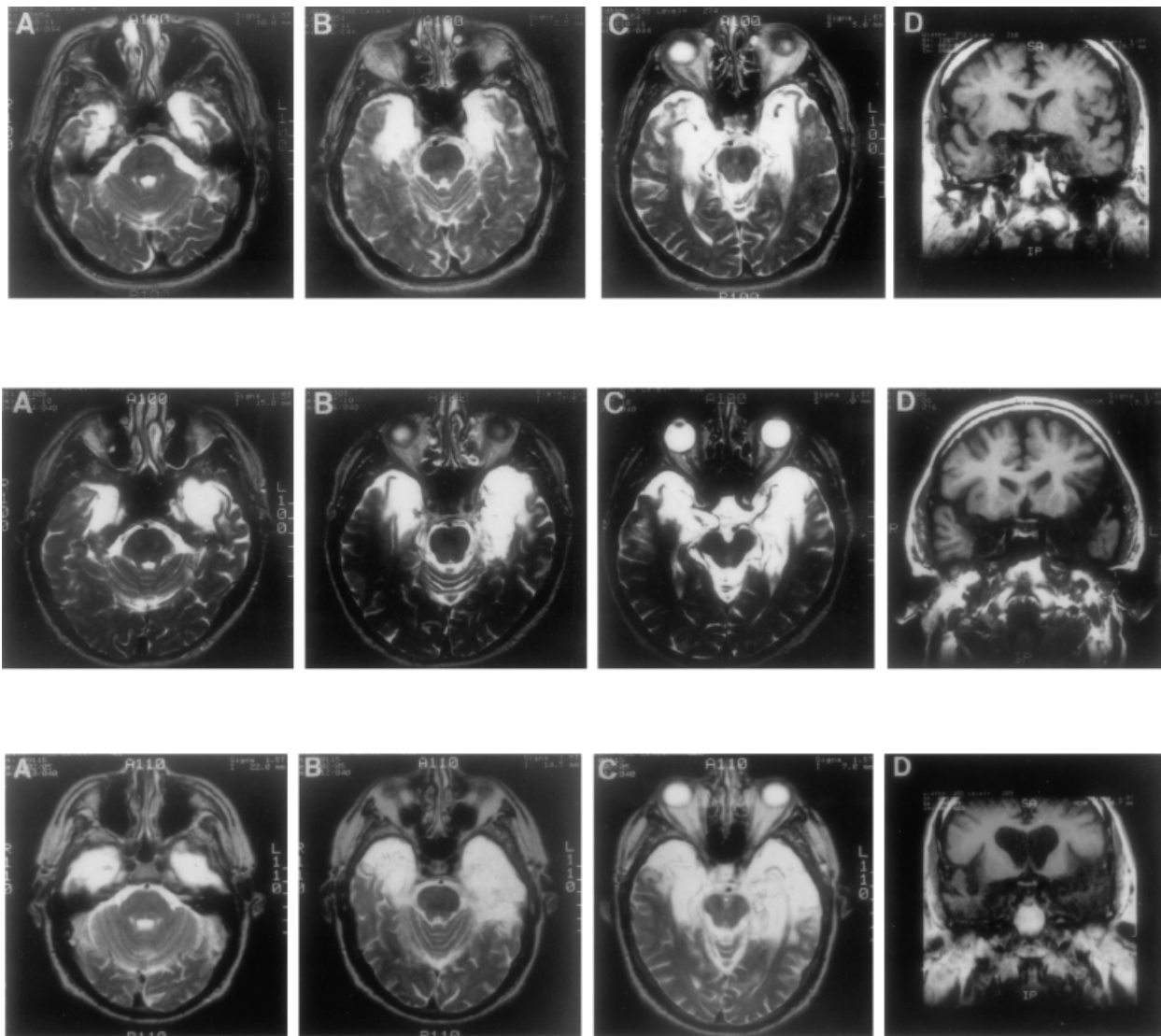


FIGURE 1. Magnetic resonance images showing the extent of bilateral temporal lobe damage in patients E.P. (top row), G.P. (middle row), and G.T. (bottom row). A–C in each row are T2-weighted axial images through the temporal lobe. The images are continuous 5-mm sections (with 2.5-mm gaps) and are arranged from ventral (A) to dorsal (C). Damaged tissue is indicated by bright signal. D in each row is a coronal T1-weighted image at the level of the amygdala. Damaged tissue is indicated by dark signal. See text for detailed description of the lesions.

mation is present, although the tissue appears to be “somewhat atrophic bilaterally” and is likely deafferented due to removal of the entorhinal cortex (Corkin et al., 1997). Laterally, the lesion spares the fusiform gyrus, but there is damage at the temporal pole bilaterally that compromises the rostralmost aspects of the middle and superior temporal gyri (Corkin et al., 1997) (Fig. 3K; see also Fig. 5C,D). In addition, “the subcortical white matter associated with the anterior portions of the superior, middle, and inferior temporal gyri may also have been compromised by the resection” (p. 3975).

Amnesic patients with damage limited to the hippocampal formation (HF)

Patient A.B. A.B. developed moderately severe amnesia after a cardiac arrest in 1976. He is unable to participate in MRI studies

because he wears a pacemaker. In 2001, we obtained computed tomograph (CT) images in a GE Light Speed Plus Helical CT scanner (2 mm and 5 mm-thick axial sections, as well as 1.25 mm and 2.5 mm-thick coronal sections through the brain). The CT scan demonstrated some volume loss in the supraventricular portions of the frontal and parietal lobes, the medial occipital lobes, and the superior aspect of the cerebellar hemispheres. In contrast, temporal lobe volume appeared normal, and the temporal horns were symmetric and normal in size. Thus there was no sign of temporal lobe atrophy. Further, within the temporal lobe there was no sign of stroke, encephalitis, abscess, or any large lesion. The basal ganglia and the thalamus also appeared normal. The only focal lesions detected were small bilateral foci (maximum diameter = 1 cm) in the white matter lateral to the head of the caudate nucleus, which appeared to be old lacunar infarctions. The finer

TABLE 1.

*Characteristics of the Participants**

Name	Year of birth	Education	WAISR			WMSIII Indices		
			Full-scale IQ	Information subtest	Vocabulary subtest	Boston naming test	Working memory	General memory
E.P.	1922	12	101	17	33	63.1	99	54
G.P.	1946	16	99	20	39	70.2	99	57
G.T.	1936	12	92	4	28	25.0	108	49
H.M.	1926	12	101	18	39	82.5	87 ^a	55 ^a
A.B.	1937	20	104	27	65	88.1	81	47
L.J.	1937	12	98	17	50	90.5	96	66
CON 1–8	1921–1929	12.4	—	23.6	58.2	87.2	—	—
Mean								

*L.J. is female; the other participants are male. Indices of the the Wechsler Adult Intelligence Scale-Revised (WAIS-R) and the Wechsler Memory Scale-III (WMS-III) yield a mean score of 100 in the normal population with a SD of 15.

^aH.M.'s scores are for the Attention/Concentration and Delayed Memory indices from the Wechsler Memory Scale-Revised (WMS-R).

anatomy of the medial temporal lobe was not evident in the CT scan due to beam-hardening artifact in the coronal plane.

In view of the normal findings in the temporal lobe and a normal neurological exam (other than memory impairment), the extent of A.B.'s damage appears to be quite limited. Within the medial temporal lobe, the region most vulnerable to anoxic damage is the hippocampal formation (Caine and Watson, 2000). Further, anoxic damage limited largely to the hippocampal formation, in the absence of damage to basal ganglia, diencephalon, or basal forebrain (except the medial septal nuclei), has been described in an amnesic patient where detailed neuropsychological and neurohistological information were available. (patient L.M.; Rempel-Clower et al., 1996). It therefore seems likely that A.B.'s memory impairment is due to damage within the hippocampal formation.

Patient L.J. L.J. developed moderately severe amnesia during a 6-month period beginning in late 1988, and her memory impairment has remained stable since that time. MRI identified hippocampal formation damage bilaterally (Reed and Squire, 1998). Measured against three age- and sex-matched controls, her hippocampal region relative to the temporal lobe is reduced in area by 46%. The size of the parahippocampal gyrus and of the lateral temporal lobe is within control values.

Healthy controls (CON)

Eight healthy men were recruited from volunteers at the San Diego Veterans Affairs Medical Center and the UCSD retirement community. They were matched to the older patients with respect to age (74.0 years) and education (12.4 years; see Table 1).

Materials

All participants were given nine tests on three to five separate occasions. Seven of the tests are from the Semantic Test Battery, as originally introduced by Hodges et al. (1992a) and subsequently

amended (Garrard et al., 1997; see also Hodges et al., 1996, 1999). We constructed two additional tests (tests 2 and 9; see below). All nine tests were based on the same line drawings (Snodgrass and Vanderwart, 1980) of 24 animals and 24 objects (or their names). Each of the 48 items could further be assigned to one of 8 categories: 6 domestic land animals, 6 foreign land animals, 6 water creatures, 6 birds, 6 electrical household items, 6 nonelectrical household items, 6 vehicles, and 6 musical instruments. Unless stated otherwise, there was no time limit for the tests.

1. *Pointing to Picture (cue: Name)*: Participants were given the name of each of 48 items as a cue and were asked to identify the appropriate picture from among eight pictures in the same category.
2. *Pointing to Picture (cue: Description)*: Participants were given a verbal description of each of 48 items as a cue (without mention of physical attributes) and asked to identify the appropriate picture from among eight pictures in the same category.
3. *Naming (cue: Picture)*: Participants were shown a picture of each of 48 items as a cue and asked to name it.
4. *Naming (cue: Description)*: Participants were given a verbal description of each of 48 items as a cue and asked to name it.
5. *Semantic Features*: Participants were asked eight yes/no questions about each of 24 items, 4 questions about an item's physical features and 4 questions about an item's associative (nonphysical) features, e.g., Is a toaster round? Does a zebra live in Africa?
6. *Category Fluency*: Participants were asked to name as many examples as they could from each of 8 categories: 4 categories of living things (Animals, Birds, Water Creatures, Breeds of Dogs) and 4 categories of nonliving things (Household Items, Vehicles, Musical Instruments, and Types of Boat). For each of the eight categories, participants were given 1 min to respond.
7. *Category Sorting*: Participants were first asked to sort pictures of all 48 items into one of two categories (living/manmade). Then they sorted the 24 items from each of these two categories into narrower categories (sort the "living" items into land animals,

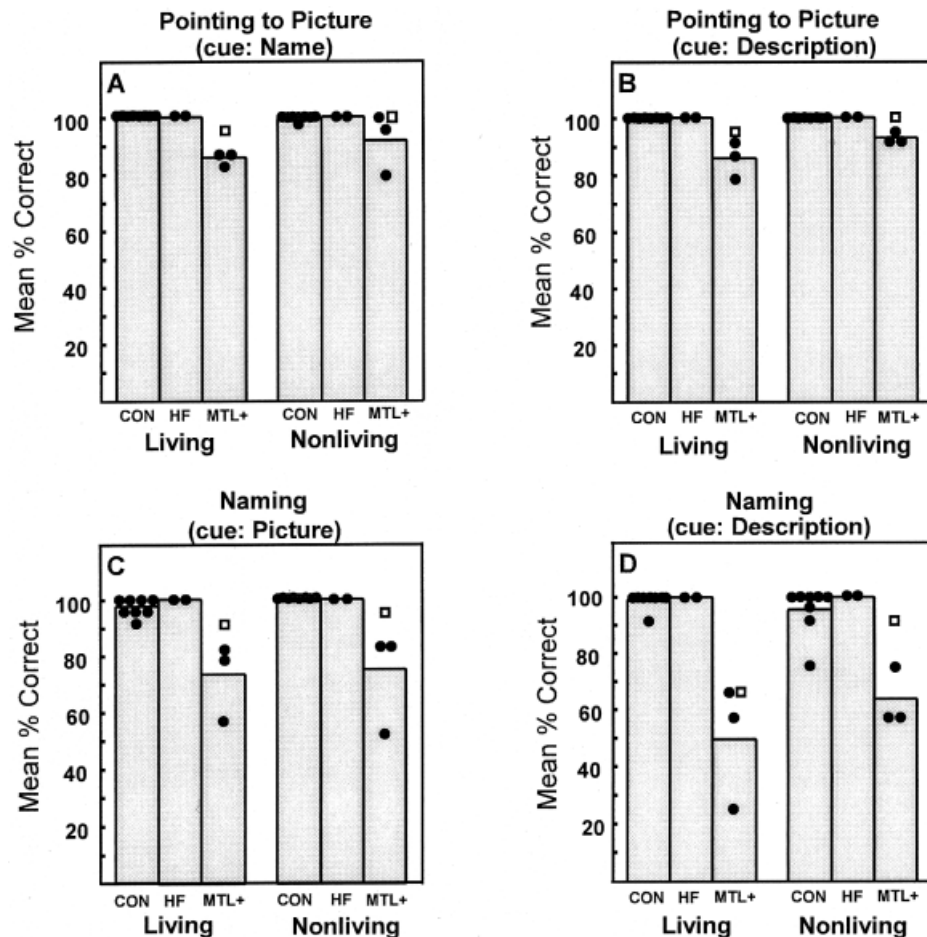


FIGURE 2. The same 48 items were used for four different tests. A: Participants were given the name of an item and were asked to identify the appropriate picture from among eight pictures of the same category (test 1). B: Participants were given a verbal description of an item and asked to identify the appropriate picture from among eight pictures of the same category (test 2). C: Participants were shown a picture of an item and asked to name it (test 3). D: Participants were given a verbal description of an item and asked to name it (test 4). CON, 8 healthy controls; HF, 2 amnesic patients with hippocampal formation damage; MTL+, 3 patients with large medial temporal lobe lesions and variable additional damage to the anterolateral temporal lobe. Circles show individual scores within each group. Squares show scores for patient H.M.

birds, or water creatures; sort the manmade things into household items, vehicles, or musical instruments). Then, they sorted 12 land animals and 12 household items three different times into still narrower categories (e.g., sort the land animals into foreign/domestic animals, fierce/nonfierce animals, and animals larger/smaller than a German Shepherd dog).

8. *Definitions to Name*: Participants were given the name of each of the 24 least common items and were asked to define it (i.e., as if he/she were explaining the item to someone who does not know what it is and has never seen it before). A card with the name of the item was in view, and 1 minute was allowed for each definition.

9. *Definitions to Picture*: Participants were shown the picture of each of the 24 least common items and asked to define it. A line drawing of the item was in view, and 1 min was allowed for each definition.

Scoring

For all but tests 6, 8, and 9, performance was measured as percentage correct. For test 6, the score was the total number of

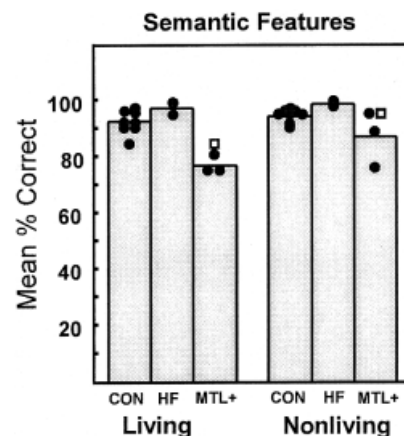


FIGURE 3. Participants were asked eight yes/no questions about each of 24 items (test 5). Circles show the individual scores within each group. Squares show scores for patient H.M. Abbreviations as in Fig. 2.

TABLE 2. *Examples of Individual Definitions Receiving a Particular Rating*

Rating	Example
4	It is a bird, quite large, about 2 feet high. It is nocturnal. It eats meat. It makes a hooting sound. It has very, very large eyes. It can swivel its neck around almost 360 degrees. It is considered wise. Its feathers don't rustle when it flies, so it can get small prey like rats and mice (OWL; C 3).
3	It has 4 legs and is 6–7 feet long. It has a large mouth and head, and a lot of teeth. It is a native of the tropics, of tropical rivers and swamps. It swims. It eats fish and other things it can catch. They come from underneath and grab it. They are vicious, you want to avoid them. They have a hard skin, almost like a piece of leather and they have sharp claws (CROCODILE; E.P.)
2	It is a bird that flies. It is used for Halloween. The face shape is different, it has ears and big eyes (OWL; G.T.)
1	It is an animal with one or two horns on its snout, buggy eyes, and excessive weight (may be 1500–1800 pounds). It lives in and by the water. It is vegetarian, eats growth under water. It can stay under water 1–2 minutes and is graceful there. It has susceptible tender skin that can get sunburned like human's (RHINOCEROS; C 2)
0	It is a large bird, about 1½ to 2 feet, but variable. Its wings open up to a surprising size. It doesn't fly much. They are friendly and not aggressive. They are graceful fliers; they don't have to move their wings; they fly to a certain height, then glide (OWL; G.P.)

Participants were asked to provide a definition of each item (i.e., as if he/she were explaining it to someone who does not know what it is and has never seen it before). A line drawing of the item was in view, and 1 min was allowed per item. The examples were edited from transcripts to improve readability.

category exemplars that were produced. For tests 8 and 9, the sessions were tape-recorded and later transcribed. We then determined for each definition the number of correct statements and the number of erroneous statements. We also assigned a quality score (0–4) to each definition. A score of 4 denoted definitions that contained many important attributes and that allowed the item being defined to be readily recognized. A score of 3 denoted definitions that allowed the item being defined to be identified, but these definitions omitted important attributes or contained minor errors. A score of 2 denoted definitions that omitted attributes important for distinguishing the item from a related item, or definitions that contained errors that made it difficult to identify an item. A score of 1 denoted definitions that were vague and scarcely interpretable, or definitions containing major errors that suggested an item different from the one being defined. A score of 0 was given to definitions that were not interpretable at all, either because attributes needed for identification were omitted or because the definitions described the wrong item. Table 2 illustrates definitions from test 9 that obtained a score of 0, 1, 2, 3, or 4.

To assess the reliability of the 0–4 scoring method, we also asked 14 raters (mean age = 67; mean = 16 years of education) to try to identify from the edited transcripts for test 8 (Definition to Name) what items were being defined. Each rater scored 24 different test items, including 2–3 definitions from each participant. Raters were first asked to try to identify each item that was defined and to guess if necessary. They were then asked to assign a score to each definition (0–4). This procedure was applied to the response of patients E.P., G.P., and G.T. and to four of the controls.

In addition, for each participant, we evaluated four verbatim, transcribed definitions from test 8 for grammatical errors and for errors of form. The four items evaluated were the two items that

were the easiest to define (Lion and Motorcycle) and the two items that were most difficult (Swan and Spinning Wheel). Because participants tended not to speak in complete sentences, we assessed the frequency of errors within phrases or sentence fragments. For each definition, we determined the frequency of sentence fragments containing grammatical errors, including the use of incorrect or confusing references and the use of words or expressions that were incorrect or inappropriate to the context. We also determined the frequency of errors in form, including incomplete or meaningless phrases and immediate repetitions of a phrase (or repetition of a phrase after only one intervening sentence fragment).

Other Tests of Semantic Knowledge

We also gave four additional tests that have been used previously to examine semantic knowledge in patients with semantic dementia or Alzheimer's disease (e.g., Breedin et al., 1994; Srinivas et al., 1997; Ullmann et al., 1997; Hodges et al., 1999). Only the Pyramids and Palm Trees Test was given to H.M. In the Object/Non-object Discrimination Task (Kroll and Potter, 1984; Riddoch and Humphreys, 1987), participants saw 30 line drawings of real objects and 30 line drawings of non-objects (created by cutting and pasting parts of real objects) and were asked to indicate whether the object was real or not. In the Coloring Object Task (Srinivas et al., 1997), participants were asked to color 28 line drawings of objects (Snodgrass and Vanderwart, 1980) with the appropriate colored pencil. Four different colors were provided. In the Pyramids and Palm Trees Test (Howard and Patterson, 1992), participants were shown 52 cards, each containing a target picture and two test pictures. Patients were asked to indicate which one of the test

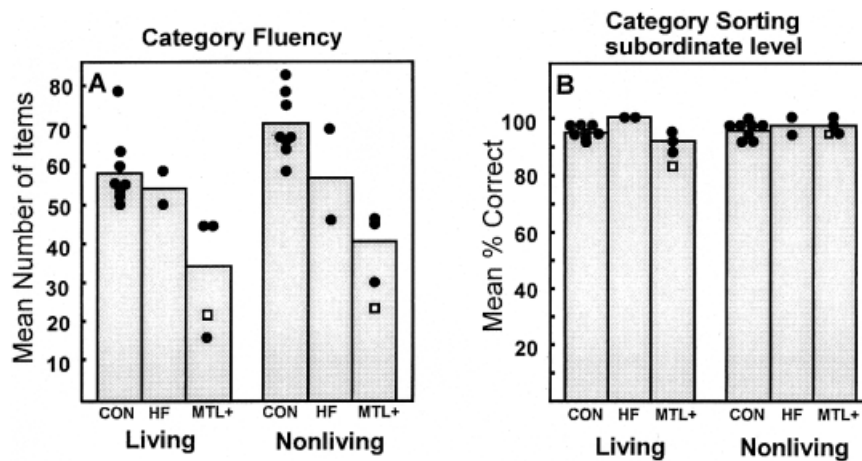


FIGURE 4. A: Participants were asked to name in 1 min as many examples as they could from each of four categories of living things and 4 categories of nonliving things (test 6). B: Participants were asked to sort 12 land animals and 12 household items into 3 subordinate categories each, e.g., foreign/domestic animals, fierce/nonfierce animals, and animals larger/smaller than a German Shepherd dog (test 7). Circles show the individual scores within each group. Squares show scores for patient H.M. Abbreviations as in Fig. 2.

pictures “goes with” the target picture. For example, a saddle was presented above drawings of a horse and a goat, and the participant was asked: “Which one goes with the saddle?” In the “word version” of this test, participants performed the same task with three words instead of three pictures. In the Nouns and Verbs Test (Ullmann and Corkin, 1997; Ullmann et al., 1997; Kensinger et al., 2001), participants were asked to produce 64 irregular and 64 regular past tenses, and 16 regular and 16 irregular plurals. Each test item was presented as two short sentences, and participants were asked to fill in the blank in the second sentence. For example, “Every day I take a banana. Just like every day, yesterday I ___ a banana.” or “The hoof is hard. In fact, most ___ are hard.”

RESULTS

Semantic Test Battery

Figure 2 shows performance on the two pointing tasks and the two naming tests. Controls (CON) and amnesic patients (HF) performed nearly without error on all four tests. By contrast, the three patients with large medial temporal lobe lesions (MTL+: E.P., G.P., and G.T.) were mildly but significantly impaired on each task ($P < 0.005$). Overall, the controls scored 98.9% correct, the HF patients scored 100% correct, and the three MTL+ patients scored 78.1% correct. H.M. performed close to the control level on three of the four tests (Fig. 2A–C, 96.5% correct for H.M.; 99.5% correct for controls). On the test that asked him to name living things when given their descriptions, however, he scored only 66.7% correct (Fig. 2D, left), well outside the range of control scores. The three patients with MTL+ lesions and H.M. scored more poorly on questions about living things than on questions about nonliving things (74.0% vs 80.9% for MTL+; 87.5 vs 96.9% for H.M.; for all four patients, $t[3] = 3.3$; $P < 0.05$). It is important to note that the impairment exhibited by these patients

is not limited to a difficulty in naming. For example, performance was similar on the two pointing tasks (Fig. 2A,B), even though the name of the item was relevant in only one of the tasks (A).

Figure 3 shows performance on test 5 (Semantic Features). As was the case for tests 1–4, the two HF patients performed well (96.9% correct vs 91.9% correct for the controls). In contrast, the three patients with MTL+ lesions were significantly impaired (80.9% vs 91.9%; $t[9] = 3.7$, $P = 0.005$). For nonliving things alone (Figure 3, right panel), the impairment was marginal (85.8% vs 92.8%, $P < 0.10$; living things alone, 76.0% vs 91.0% correct; $t[9] = 5.2$, $P = 0.001$). H.M. performed similarly to the poorest control on questions about living items (85.4% correct), and he obtained a normal score on questions about nonliving items (95.8% correct).

Figure 4 shows performance on the Category Fluency and Category Sorting Tests (tests 6 and 7). Figure 4A shows that controls generated an average of 128.9 items (for both living and nonliving things), the two HF patients generated 112.0 items, and the three MTL+ patients generated 75.7 items ($t[9] = 4.4$, $P < 0.005$, for CON vs MTL+). Patient G.T. had particular difficulty with living things (16 total items generated). It was notable that he was not able to name a single type of dog, although he had bred dogs for many years. Extended cueing in a later, casual conversation also did not enable him to name any kinds of dog. H.M. was impaired for both living (21 exemplars; control mean = 58.5) and for nonliving items (22 exemplars; control mean = 70.4).

On the Category Sorting test, all the participants performed well overall. They were able to sort the 48 cards with line drawings into superordinate, ordinate, and subordinate categories virtually without error (overall score: CON, 97.0% correct, HF, 98.5% correct; MTL+, 97.0% correct, and H.M., 93.5% correct). For subordinate categories (Fig. 4B), H.M. sorted fewer cards correctly than any other participant (88.9% correct overall).

Figure 5 shows the scores (0–4 scale) when participants were given the name of each of the 24 test items and asked to define the item (Fig. 5A), and when they were shown a picture of each item and asked to

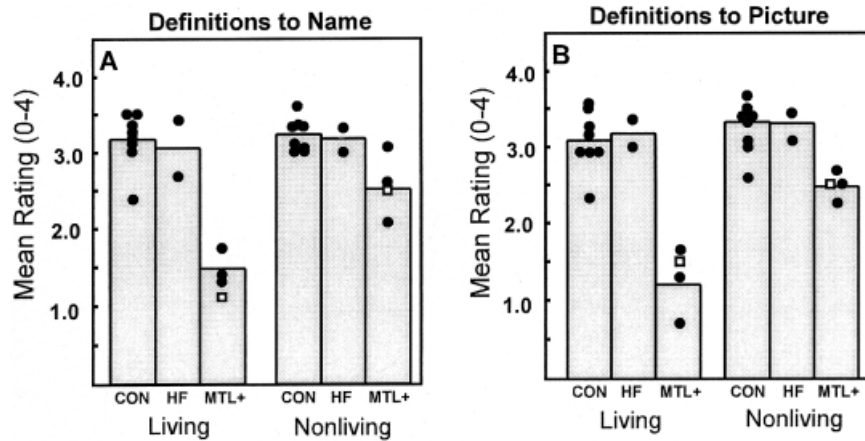


FIGURE 5. A: Participants were given the name of each of 24 items and asked to define the item. Responses were scored on a 0–4 scale (test 8). B: Participants were shown a picture of each of the same 24 items and asked to define each item. Responses were scored on a 0–4 scale (test 9). Circles show the individual scores within each group. Squares show scores for patient H.M. Abbreviations as in Fig. 2.

define the item (Fig. 5B). The definitions provided by the MTL+ group were of lower quality than the definitions provided by the controls. The two HF patients obtained normal scores. The controls obtained scores of 3.2 and 3.2 across all tests (Fig. 5A, B), the amnesic patients obtained scores of 2.0 and 1.8 (MTL+ group vs CON, $t[9] > 6.9$, $P < 0.001$). When blind raters were asked to identify which items had been defined, they were able to identify correctly more definitions from controls than from patients (87.1% vs 59.7%, respectively, $t[5] = 9.8$, $P < 0.001$, for CON vs MTL+). Moreover, for the definitions that the raters could identify correctly, they assigned higher scores to the controls than to the MTL+ group (3.4 vs 3.1, $t[5] = 3.3$; $P < 0.05$). The definitions by the MTL+ group contained fewer correct statements per item (6.1) and more errors per item (0.8) than the definitions provided by either the controls (10.2 correct statements and 0.2 errors per item; $t[9] s > 4.4$, $P < 0.002$) or the HF

group (9.9 correct statements and 0.2 errors). H.M. performed similarly to the three patients with MTL+ lesions. His scores on the 0–4 scale were 1.8 and 2.0 (Fig. 5A and 5B, respectively). Further, his definitions contained 7.1 correct statements per item, with 0.9 errors.

In summary, patients in the MTL+ group, as well as H.M., provided definitions with impoverished detail and many errors, and they had difficulty making the items they were defining identifiable. Because performance was poor when definitions were attempted with the picture of the item in view, and not just when the name of the item was provided, the impairment was not due to impaired name comprehension.

Figure 6 shows the frequency of grammatical errors (A) and form errors (B) that were produced in the course of providing definitions. The data are shown separately for two easy items (lion and motorcycle) and two difficult items (swan and spinning

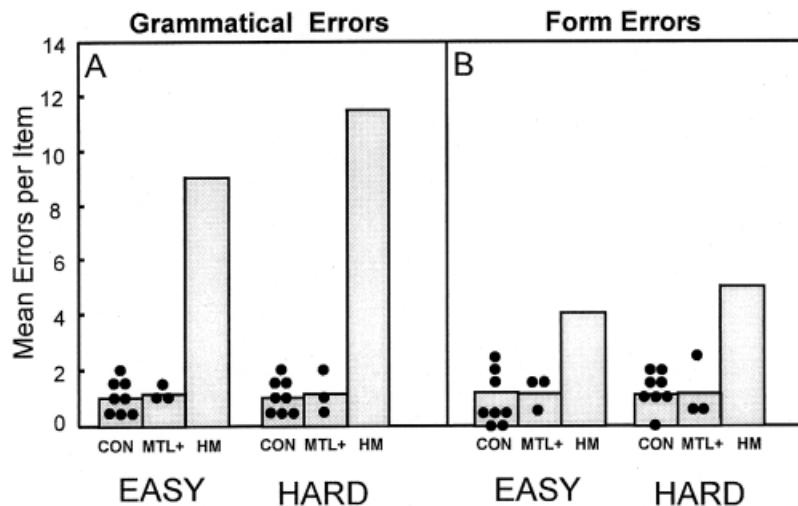


FIGURE 6. Transcripts from definitions (from Fig. 5A, test 8) were assessed for the frequency of both grammatical errors (A) and form errors (B). The two easy items were lion and motorcycle, and the two hard items were swan and spinning wheel. Circles show the individual scores within each group. Abbreviations as in Fig. 2.

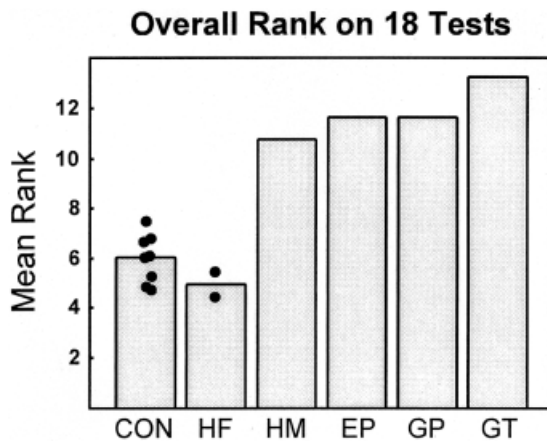


FIGURE 7. The performance of each participant was ranked on each of the 18 tests (9 tests concerning living items and 9 tests concerning nonliving items; data from Figs. 2–5). Bars show the mean rank obtained. Circles show the mean rank for individual controls. Controls obtained an average rank of 6.0 among all 14 participants, because performance on the 18 tests was close to normal for 10 of the 14 participants. Accordingly, on any one test, a control's rank could range from 1 to 10. In the four patients with more extensive lesions, the ranking demonstrates a relationship between performance on tests of semantic knowledge and the amount of damage to anterolateral temporal cortex.

wheel). H.M. made many errors in the course of defining these items. In contrast, none of the three MTL+ patients made a noticeable number of errors. Interestingly, H.M. made about as many errors defining “easy” items as “hard” items. On average, each of H.M.'s definitions contained 10.3 grammatical errors (4.5 incorrect or confusing references, 2.8 incorrect words or expressions, and 3.0 phrases that contained other grammatical errors; <1 in each category for controls and MTL+ patients). Further, on average, each of H.M.'s definitions contained 4.5 form errors (3.0 incomplete phrases and 1.5 repeated phrases; <1.0 in each category for CON and MTL+ patients). The Appendix provides excerpts from verbatim transcripts for patients H.M., G.T., and a CON, showing examples from each error category. These errors in grammar and form were observed uniquely in H.M.'s definitions, despite the fact that his quality scores (0–4 scale) for these same definitions were similar to the scores of the MTL+ patients. (H.M. scored 3.0, 3.0, 0, and 1.0, for lion, motorcycle, swan and spinning wheel, respectively; corresponding scores for the MTL+ group were 2.8, 3.3, 0.8, and 1.0, respectively.)

Comparing Performance Among Patients

For each of the 18 separate tests (living and nonliving items on each of 9 tests; data from Figures 2–5), we ranked the performance of all 13 participants. Figure 7 shows the mean rank for each of the patients with MTL+ lesions, the mean for the controls (CON), and the mean ranks for the two HF patients. Amnesic patients ranked slightly higher than controls, perhaps because they were younger and/or better educated (ranks of 4.4 and 5.6 for the two patients, mean rank for controls: 6.0). Among the other four patients, there was a direct relation between performance on the 18

tests and the extent of damage to lateral temporal cortex. That is, their ranking on the 18 tests from highest (H.M.) to lowest (G.T.) was the same as their ranking with respect to amount of lateral cortex damage (H.M. least, G.T. most).

Living Versus Nonliving Items

On most of the nine tests, patients with MTL+ lesions, including H.M., had more difficulty with living items than with nonliving items (Figs. 2–5). This difference was significant for the scores in Figures 2 (A–D, combined), 4B, and 5 ($t[3] > 3.3$, $P_s < 0.05$), and fell just short of significance for scores in Figure 3 ($P = 0.07$). This same difference was described previously in patients with postencephalitic lesions of the ventral temporal lobe (Warrington and Shallice, 1984; Caramazza and Shelton, 1998). The finding has been attributed to differences in visual complexity (e.g., Funnel and Sheridan, 1992) or feature overlap (e.g., Riddoch and Humphreys, 1987) among the stimuli commonly used to depict living and nonliving items. There is also evidence that the particular sensory and motor systems involved in learning about objects influence which brain areas store their representations (e.g., Warrington and McCarthy, 1988; Martin et al., 1996; Farah et al., 1996; Tranel et al., 1997).

Naming and Knowing

The relationship between the ability to name items and to provide semantic knowledge about the same items was examined in more detail in the case of the four patients with MTL+ lesions. For the naming test in Figure 2C, we first identified the items that patients named successfully (i.e., spontaneously and without cues from the examiner) and the items that they could not name. Then, for tests of semantic knowledge that did not explicitly require naming (Figs. 3, 5B), we compared performance for items that had been named successfully and items that had not been named. For both tests, the average score for items that had been named was higher than for items that had not been named ($P < 0.005$). Thus, for the patients with MTL+ lesions, the failure to name an item spontaneously predicted that less semantic knowledge would be available about that item than would be available for other items that could be named. A relationship between naming ability and semantic knowledge has also been described in patients with mild Alzheimer's disease. (Hodges et al., 1996).

Other Tests of Semantic Knowledge

Table 3 shows the results for four additional tests of semantic memory.

Object/nonobject discrimination test

When asked whether objects were real or not, two patients (E.P. and G.T.) performed as well as controls. E.P. made one error, and G.T. made no errors; G.P. made eight errors.

Coloring objects

One patient performed well within the control range (G.P.). Two patients made more errors than controls and performed out-

TABLE 3.

Scores on Four Tests Used to Assess Semantic Knowledge*

Name	Object/nonobject	Color object	Pyramids and Palm Trees		Nouns and Verbs	
			Nonverbal	Verbal	Regular nouns and verbs	Irregular nouns and verbs
E.P.	98.3	82.0	94.2	90.4	100	82.8
G.P.	86.7	92.9	88.5	80.8	100	80.5
G.T.	100	75.0	88.5	88.5	99.2	69.8
H.M.	—	—	86.5	82.7	96	91
CON	95.8 ^a	92.0 ^a	97.4	97.6	99.6 ^a	90.2 ^a
range	93.3–98.3	85.7–100	90.4–100	92.3–100	99.2–100	84.4–97.6

*Scores are given in percentage correct. Data for H.M. on the Nouns and Verbs Test are from Kensinger et al. (1999).

^aThese means are based on four controls rather than eight.

side the control range, although this difference did not reach statistical significance (78.5% versus 92% correct; $t[4] = 2.27$, $P = 0.07$, for CON versus E.P. and G.T.). For the nonverbal and verbal versions of the Pyramids and Palm Trees Test, Howard and Patterson (1992) suggested a “cutoff score” of 90% correct to identify impaired performance (normative sample mean of 98.5%). On the nonverbal test, G.T., G.P., and H.M. performed outside the range of the eight controls and below 90% correct. On the verbal test, all four patients performed outside the control range, and all but E.P. scored below 90% correct.

Nouns and verbs test

The CON group and the MTL+ group performed similarly when asked to produce regular verb and plural forms (99.6% correct and 99.7% correct, respectively). The MTL+ group was impaired at producing irregular verb and irregular plural forms (77.7% correct versus 90.9% correct for controls, $t[5] = 3.0$, $P < 0.05$). This impairment has been described previously in patients with damage to anterolateral temporal cortex (Patterson et al., 2001). H.M. scored well: 96% for regular forms and 91% correct for irregular forms (Kensinger et al., 1999; also see Kensinger et al., 2001).

DISCUSSION

To investigate the effects of damage to the medial temporal lobe and anterolateral temporal cortex on semantic knowledge, we studied three postencephalitic patients with extensive MTL damage and variable damage to lateral temporal cortex (MTL+), patient H.M. (whose damage is for the most part limited to the MTL but who has additional damage to anterolateral temporal cortex), two patients with HF damage, and eight control subjects. A series of nine tests involving 24 living and 24 nonliving items was given, along with four additional tests of semantic knowledge. The HF

patients performed similarly to controls in all respects. The three MTL+ patients were mildly to moderately impaired on most of the tests. H.M.’s scores were borderline on most of the tests and were unequivocally impaired on 5 of the 11 tests that he performed (Figs. 2D, 4A, 5A,B; Table 3). When we ranked the scores on the 9 tests for all participants, there was a relation between performance and the extent of damage to lateral temporal cortex. This relation was particularly clear among the four patients with MTL+ lesions.

The results reported in this study are consistent with recent studies of the ability to detect and explain ambiguity in sentences. In one study, patients with HF lesions performed normally, but three MTL+ patients were impaired (Schmolck et al., 2000). In an earlier study with similar materials, H.M. was also found to be impaired (MacKay et al., 1998b).

Degradation of semantic knowledge has been studied extensively in the syndrome of semantic dementia, which is characterized by a progressive loss of fluent speech and a gradual deterioration of knowledge about the world (Hodges et al., 1992b, 2000; Lambon Ralph et al., 1998, 2001). Anterograde and retrograde memory for episodes remain largely intact. The severity of impaired semantic knowledge in our patients was much milder than that described in semantic dementia (Hodges et al., 1999). For example, when asked to name an item with the picture of the item in view (Fig. 2C), patients with semantic dementia were able to name only 21% of the items (74% for the three MTL+ patients; 94% for H.M.; 98% for controls). When asked to point to a picture in response to its name (Fig. 2A), the patients with semantic dementia scored 62% correct (89% for the three MTL+ patients; 98% for H.M.; 99.7% for CON). In a single-case study of semantic dementia (Srinivas et al., 1997), patient D.M. was also more severely impaired than our patients. When asked to color objects appropriately, D.M. scored 35.7% correct, compared to 75% correct or better for our patients. When asked to decide whether objects were real or not, D.M. scored 78.3% correct (our patients, better than 86%). On the Pyramids and Palm Trees Test, D.M. scored 60% correct (our patients, better than 84%). Overall,

the pattern of impairment in our patients is consistent with a loss of specific information from a network of conceptual knowledge (Murre et al., 2001), which results in a “blurring” of some concepts and overlap among concepts that are closely related.

Semantic Knowledge and the Medial and Lateral Temporal Lobes

Several lines of evidence suggest that impaired semantic knowledge is related to damage in anterolateral temporal cortex and not medial temporal lobe structures, including perirhinal cortex. First, patients with semantic dementia typically have atrophy of the lateral temporal cortex and the temporal pole, with relative sparing of the medial temporal lobe and other cortical areas (Hodges et al., 1992; Garrard et al., 1997). In a recent morphometric MRI study of six patients, the most consistent locus of atrophy was the left polar and inferior temporal lobe (Mummery et al., 2000). More medial cortex appears not to be compromised, at least in the early stages of the disease. Although the status of the polar portion of perirhinal cortex in semantic dementia is uncertain, there is a strong correlation between the severity of semantic dementia and the degree of anterolateral temporal lobe atrophy (Simons et al., 1999; Mummery et al., 2000). A recent study found that the volume of the left fusiform gyrus best correlated with measures of semantic knowledge and that measures of naming were additionally correlated with the volumes of the left temporal pole and the inferior and middle temporal gyri (Galton et al. 2001; for the importance of anterior temporal lobe structures in semantic dementia, see also Chan et al., 2001). It is also noteworthy that recognition memory is impaired by damage to perirhinal cortex (Meunier et al., 1993; Buffalo et al., 1998, 1999). Yet patients with semantic dementia exhibit intact recognition memory, even though they exhibit severe impairment on tests of semantic knowledge about the same stimuli (Simons et al., 1999).

Other evidence about the anatomy of semantic knowledge comes from functional neuroimaging studies. Within the temporal lobe, making semantic judgments about either words or pictures activated the left inferior temporal gyrus, the left middle temporal gyrus, and the left fusiform gyrus (Vandenberghe et al., 1996). Similarly, lexico-semantic processing of words and word meanings was associated with activity in the left middle and left inferior temporal gyri (Demonet et al., 1992). Finally, when volunteers generated appropriate color names or action words in response to either line drawings of objects or written names of the objects, activity was observed in the temporal lobe in the fusiform gyrus (for color words) and in the left posterior middle and superior temporal gyri (for action words) (Martin et al., 1995). For additional findings, see the comprehensive review by Cabeza and Nyberg (2000).

Another source of evidence comes from brain stimulation studies of patients who are candidates for unilateral temporal lobectomy. Stimulation in the inferior temporal lobe (the basal temporal language area) caused speech arrest and impaired confrontation naming (Luders et al., 1986). The area in which language disturbance could be produced included the inferior temporal gyrus, fusiform gyrus, and parahippocampal gyrus (Burnstine et al., 1990; Schaffler et al., 1994). The area in which stimulation most

consistently produced speech errors was the fusiform gyrus (Schaffler et al., 1994).

A final line of evidence comes from studies of confrontation naming. Impaired confrontation naming (dysnomia) is related to damage lateral to the medial temporal lobe. First, patient H.M., who has large medial temporal lobe lesions, performed within 1 SD of the control mean on a standard test of picture naming (the Boston Naming Test) (Kensinger et al., 2001). Second, impaired confrontation naming is found following left anterior temporal lobectomy (Langfitt and Rausch, 1996; Hermann et al., 1999; Hermann et al., 1994). In a recent study that assessed 217 patients across eight centers, the severity of postoperative naming problems was related to the lateral extent of the resection (Hermann et al., 1999). Notably, language impairment following left anterior temporal lobectomy is not limited to difficulty with naming but also includes difficulty in other tasks of semantic knowledge, such as those tasks that assess the ability to comprehend nouns and make judgments about synonyms (Glosser and Donofrio, 2001).

In summary, findings from semantic dementia, neuroimaging, brain stimulation, and unilateral temporal lobectomy point to the importance of lateral temporal cortex for semantic knowledge. Moreover, the severity of the impairment in semantic knowledge in our patients was related to the extent of damage to lateral temporal cortex. Accordingly, we propose that the impairments exhibited by our three postencephalitic patients, and the milder impairments exhibited by H.M., are due to damage to anterolateral temporal cortex, lateral to the medial temporal lobe. While it is difficult to exclude entirely a possible contribution of damage to structures within the parahippocampal gyrus (entorhinal, perirhinal, and parahippocampal cortex), this possibility seems unlikely. Thus, patients G.T., G.P., and E.P. all have complete damage to the perirhinal and entorhinal cortices; yet G.T. performed overall more poorly on the tests of semantic knowledge than did G.P. or E.P.

These considerations appear to rule out a contribution of the perirhinal and entorhinal cortices to deficits in semantic knowledge. Nevertheless, it was the case that damage within the parahippocampal cortex itself did relate to the severity of the impairment in semantic knowledge in our three patients (E.P. = 40% damage bilaterally, G.P. = 42%, and G.T. = 72%). However, H.M. had impairments in semantic knowledge despite the fact that his parahippocampal cortex was largely intact. Thus, while additional cases will be useful to settle this point, damage to structures within the parahippocampal gyrus do not appear to be a significant factor in impaired semantic knowledge (also see Galton et al., 2001).

The Special Case of Patient H.M.

In a recent, comprehensive study of H.M.’s language capacities, no evidence was found for impaired lexical knowledge or impaired production of regular and irregular word forms (Kensinger et al., 2001). On the tests of semantic knowledge studied here, H.M. performed within the range of control scores on most of the tests that we gave him. He performed outside the control range when he had to name items in response to their descriptions (Fig. 2D), when he had to generate category exemplars (Fig. 4A) (see also Kensinger et al., 2001), and when he had to provide definitions

either in response to names of items (Fig. 5A) or pictures of items (Fig. 5B). He was also mildly impaired on the Pyramids and Palm Trees Test (Table 3). Kensinger et al. (2001) suggested that H.M.'s poor performance on tests of fluency may be related to motor slowing secondary to cerebellar degeneration. As for the other tests on which he had reduced scores, it is not straightforward to identify the basis for the impairment. It is notable that his shortcomings on tests of definitions resembled the difficulties that the three postencephalitic patients had on these same tests. Like them, he failed to supply the details that would make it possible to identify items and to differentiate items from other, semantically related items. Accordingly, in the case of the tests of definitions (and possibly the other tests that he performed poorly), H.M.'s impairment may have the same anatomic basis as in the patients in the MLT+ group: damage lateral to the medial temporal lobe. In H.M.'s case, this lateral damage is limited, but it may be sufficient to impair performance on sensitive tests of semantic knowledge.

H.M.'s performance was also unique in important ways. First, as described previously (Milner et al., 1968), H.M.'s intonation was monotone and little modulated. Second, while providing definitions, he made a large number of grammatical errors. For example, he made frequent errors in the use of pronouns and referents (see also MacKay et al., 1998b). (For additional examples of difficulties unique to H.M., see Schmolck et al., 2000.) In contrast, the postencephalitic patients (E.P., G.P., and G.T.), all of whom have more extensive medial and lateral lesions than H.M., spoke with normal intonation and made no more grammatical errors than did control subjects (Fig. 6). Accordingly, H.M.'s shortcomings in language production, as described in previous reports (MacKay et al., 1998a, b; MacKay and James, 2001), are unlikely to be related to his medial or lateral temporal lobe damage. H.M. had seizures beginning at age 10 (which raises the question whether his language development was fully normal), his schooling was interrupted, and he came from a low socioeconomic background. Any of these factors could be important.

In summary, patients with damage limited to the hippocampal formation (HF) performed normally in every respect on tests of semantic knowledge. In contrast, three postencephalitic patients with large medial temporal lobe lesions and variable damage to anterolateral temporal cortex (MTL+) exhibited mild to moderate impairment on these tests. Patient H.M. was impaired on five of the tests and was less severely impaired overall than were the three postencephalitic patients. Accordingly, we suggest that the deficits in semantic knowledge reported here are most likely related to cortical damage lateral to the medial temporal lobe. Finally, H.M.'s language production, including his use of grammar, distinguished him from the other patients. These features of his performance are unlikely to be related to his temporal lobe lesion.

REFERENCES

- Amaral DG, Insausti R. 1990. The human hippocampal formation. In: Paxinos G, editor. *The human nervous system*. p 711–755.
- Buffalo EA, Ramus SJ, Clark RE, Teng E, Squire LR, Zola SM. 1999. Dissociation between the effects of damage to perirhinal cortex and area TE. *Learn Mem* 6:572–599.
- Buffalo EA, Reber PJ, Squire LR. 1998. The human perirhinal cortex and recognition memory. *Hippocampus* 8:330–339.
- Burnstine TH, Lesser RP, Hart J Jr, Uematsu S, Zinreich SJ, Krauss GL, Fisher RS, Vining EPG, Gordon B. 1990. Characterization of the basal temporal language area in patients with left temporal lobe epilepsy. *Neurology* 40:966–970.
- Cabeza R, Nyberg L. 2000. Imaging cognition II: an empirical review of 275 PET and fMRI studies. *J Cogn Neurosci* 12:1–47.
- Caine D, Watson J. 2000. Neuropsychological and neuropathological sequelae of cerebral anoxia: a critical review. *J Int Neuropsychol Soc* 6:86–99.
- Caramazza A, Shelton JR. 1998. Domain specific knowledge systems in the brain: the animate–inanimate distinction. *J Cogn Neurosci* 10:1–34.
- Chan D, Fox NC, Scahill RI, Crum WR, Whitwell JL, Leschziner G, Rossor AM, Stevens JM, Cipolotti L, Rossor MN. 2001. Patterns of temporal lobe atrophy in semantic dementia and Alzheimer's disease. *Ann Neurol* 49:433–442.
- Corkin S. 1984. Lasting consequences of bilateral medial temporal lobectomy: clinical course and experimental findings in H.M. *Semin Neurol* 4:249–259.
- Corkin S, Amaral DG, Gonzalez RG, Johnson KA, Hyman BT. 1997. H.M.'s medial temporal lobe lesion: findings from magnetic resonance imaging. *J Neurosci* 17:3964–3980.
- Demonet J, Chollet F, Ramsay S, Cardebat D, Nespoulous J, Wise R, Rascol A, Frackowiak RS. 1992. The anatomy of phonological and semantic processing in normal subjects. *Brain* 115:1753–1768.
- Farah MJ, Meyer MM, McMullen PA. 1996. The living/nonliving distinction is not an artifact: giving an a priori implausible hypothesis a strong test. *Cogn Neuropsychol* 13:137–154.
- Funnell E, Sheridan J. 1992. Categories of Knowledge? Unfamiliar aspects of living and nonliving things. *Cogn Neuropsychol* 9:135–153.
- Galton CJ, Patterson K, Graham K, Lambon Ralph MA, Williams G, Antoun N, Sahakian BJ, Hodges JR. 2001. Differing patterns of temporal atrophy in Alzheimer's disease and semantic dementia. *Neurology* 57:216–225.
- Garrard P, Perry R, Hodges JR. 1997. Disorders of semantic memory. *J Neurol, Neurosurg Psychiatry* 62:431–435.
- Glosser G, Donofrio N. 2001. Differences between nouns and verbs after anterior temporal lobectomy. *Neuropsychology* 15:39–47.
- Hermann BP, Perrine K, Chelune GJ, Barr W, Loring DW, Strauss E, Trenerry MR, Weisterveld M. 1999. Visual confrontation naming following left anterior temporal lobectomy: a comparison of surgical approaches. *Neuropsychology* 13:3–9.
- Hermann BP, Wyler AR, Somes G, Clement L. 1994. Dysnomia after left anterior temporal lobectomy without functional mapping: frequency and correlates. *Neurosurgery* 35:52–57.
- Hodges JR, Bozeat S, Lambon Ralph MA, Patterson K, Spatt J. 2000. The role of conceptual knowledge in object use Evidence from semantic dementia. *Brain* 123:1913–1925.
- Hodges JR, Patterson K, Graham N, Dawson K. 1996. Naming and knowing in dementia of Alzheimer's type. *Brain Lang* 2:11–24.
- Hodges JR, Salmon DP, Butters N. 1992a. Semantic memory impairment in Alzheimer's disease: failure of access or degraded knowledge? *Neuropsychologia* 30:301–314.
- Hodges JR, Patterson K, Oxbury S, Funnell E. 1992b. Semantic dementia: progressive fluent aphasia with temporal lobe atrophy. *Brain* 115:1783–1806.
- Hodges JR, Patterson K, Ward R, Garrard P, Bak T, Perry R, Gregory C. 1999. The differentiation of semantic dementia and frontal lobe dementia from early Alzheimer's disease: a comparative neuropsychological study. *Neuropsychology* 13:31–40.

- Howard D, Patterson K. 1992. Pyramids and Palm Trees: a test of semantic access from pictures and words. Bury St. Edmunds: Thames Valley Test Company.
- Insausti R, Juottonen K, Soininen H, Insausti A, Partanen K, Vainio P, Laakso M, Pitkanen. 1998. MR Volumetric analysis of the human entorhinal, perirhinal, and temporopolar cortices. *Am J Neuroradiol* 19:659–671.
- Kensinger EA, Ullman MT, Locascio JJ, Corkin S. 1999. What is the relation between medial temporal lobe structures and lexical memory? Evidence from amnesic patient H.M. *Soc Neurosci Abs* 25:357.
- Kensinger EA, Ullman MT, Corkin S. 2001. Bilateral medial temporal lobe damage does not affect lexical or grammatical processing: evidence from amnesic patient H.M. *Hippocampus* 11:347–360.
- Lambon Ralph MA, Graham KS, Ellis AW, Hodges JR. 1998. Naming in semantic dementia—what matters? *Neuropsychologia* 8:775–784.
- Lambon Ralph MA, McClelland JL, Patterson K, Galton CJ, Hodges JR. 2001. No right to speak? The relationship between object naming and semantic impairment: neuropsychological evidence and a computational model. *J Cogn Neurosci* 13:341–356.
- Langfitt JT, Rausch R. 1996. Word finding deficits persist after left anterotemporal lobectomy. *Arch Neurol* 53:72–76.
- Luders H, Lesser RP, Hahn J, Dinner DS, Morris H, Resor S, Harrison M. 1986. Basal temporal language area demonstrated by electrical stimulation. *Neurology* 36:505–510.
- MacKay DG, James LE. 2001. The binding problem for syntax, semantics, and prosody: H.M.'s selective sentence-reading deficits under the theoretical-syndrome approach. *Lang Cogn Processes* 16:419–460.
- MacKay DG, Burke DM, Stewart R. 1998a. H.M.'s language production deficits: implications for relations between memory, semantic binding, and the hippocampal system. *J Mem Lang* 38:28–69.
- MacKay DG, Stewart R, Burke DM. 1998b. H.M. Revisited: relations between language comprehension, memory, and the hippocampal system. *J Cogn Neurosci* 10:377–394.
- Manns JR, Squire LR (in press) The medial temporal lobe and memory for facts and events. In: Baddeley A, Wilson B, Kopelman M, editors. *Handbook of memory disorders*. 2nd ed. New York: John Wiley & Sons.
- Martin A, Haxby JV, Lalonde FM, Wiggs CL, Ungerleider LG. 1995. Discrete cortical regions associated with knowledge of color and knowledge of action. *Science* 270:102–105.
- Martin A, Wiggs CL, Ungerleider LG, Haxby JV. 1996. Neural correlates of category-specific knowledge. *Nature* 379:649–652.
- Meunier M, Bachevalier J, Mishkin M, Murray EA. 1993. Effects on visual recognition of combined and separate ablations of the entorhinal and perirhinal cortex in rhesus monkeys. *J Neurosci* 13:5418–5432.
- Milner B, Corkin S, Teuber HL. 1968. Further analysis of the hippocampal amnesic syndrome: 14 year follow-up study of H.M. *Neuropsychologia* 6:215–234.
- Mummery CJ, Patterson K, Price CJ, Ashburner J, Frackowiak RS, Hodges JR. 2000. A voxel based morphometric study of semantic dementia: the relationship between temporal lobe atrophy and semantic memory. *Ann Neurol* 47:36–45.
- Murre JM, Graham KS, Hodges JR. 2001. Semantic dementia: relevance to connectionist models of long-term memory. *Brain* 124:647–675.
- Patterson K, Lambon Ralph MA, Hodges JR, McClelland JL. 2001. Deficits in irregular past-tense verb morphology associated with degraded semantic knowledge. *Neuropsychologia* 39:709–724.
- Reed JM, Squire LR. 1998. Retrograde amnesia for facts and events: findings from four new cases. *J Neurosci* 18:3943–3954.
- Rempel-Clower N, Zola-Morgan S, Squire LR, Amaral DG. 1996. Three cases of enduring memory impairment after bilateral damage limited to the hippocampal formation. *J Neurosci* 16:5233–5255.
- Riddoch J, Humphreys GW. 1987. A case of integrative visual agnosia. *Brain* 110:1431–1462.
- Schaffler L, Luders H, Morris H, Wyllie E. 1994. Anatomic distribution of cortical language sites in the basal temporal language areas in patients with left temporal lobe epilepsy. *Epilepsia* 35:525–528.
- Schmolck H, Stefanacci L, Squire LR. 2000. Detection and explanation of sentence ambiguity are unaffected by hippocampal lesions but are impaired by larger temporal lobe lesions. *Hippocampus* 10:759–770.
- Scoville WB, Milner B. 1957. Loss of recent memory after bilateral hippocampal lesions. *J Neurol Neurosurg Psychiatry* 20:11–21.
- Simons JS, Graham KS, Hodges JR. 1999. What does semantic dementia reveal about the functional role of the perirhinal cortex. *Trends Cogn Sci* 3:248–249.
- Snodgrass JG, Vanderwart M. 1980. A standardized set of 260 pictures: norms for name agreement, image agreement, familiarity, and visual complexity. *J Exp Psychol Hum Learn Mem* 6:174–215.
- Squire LR, Schmolck H, Stefanacci L. 2001. Memory, language, and neuroanatomy: a reply. *Brain Lang* 78:273–275.
- Srinivas K, Breedin SD, Branch-Coslett H, Saffran EM. 1997. Intact perceptual priming in a patient with damage to the anterior inferior temporal lobes. *Neuroscience* 9:490–511.
- Stefanacci L, Buffalo EA, Schmolck H, Squire LR. 2000. Profound amnesia following damage to the medial temporal lobe—a neuroanatomical and neuropsychological profile of patient E.P. *J Neurosci* 20:7024–7036.
- Teng E, Squire LR. 1999. Memory for places learned long ago is intact after hippocampal damage. *Nature* 400:675–677.
- Tranel D, Damasio H, Damasio AR. 1997. A neural basis for the retrieval of conceptual knowledge. *Neuropsychologia* 35:1319–1327.
- Vandenberghe R, Price C, Wise R, Josephs O, Frackowiak RS. 1996. Functional anatomy of a common semantic system for words and pictures. *Nature* 383:254–256.
- Warrington EK, McCarthy RA. 1988. The fractionation of retrograde amnesia. *Brain Cogn* 7:184–200.
- Warrington EK, Shallice T. 1984. Category specific semantic impairments. *Brain* 107:829–854.

APPENDIX

Excerpts from Verbatim Transcripts (Test 8, Definitions to Name) for Patients H.M. G.T., and Control No. 4

Experimenter interjections are in *italics*. Grammatical (G) and form (F) errors are underlined.

Patient H.M., motorcycle

...well...it can be (F)...uh, uh...a motorcycle is (F) uh...maybe...4 (F), it's on 2 wheels.... And it could be have (G) a

sidecar to it...*(uh huh)*...and uh, it's very fast too...and it can ca...carry a person in back of the driver *(uh huh)*, ...and also a sidecar (G)...*(uh huh)*... PAUSE...*(what does it look like, how does it work)*...it's got 2 wheels *(um hm)* and a motor then (G) and you have to pump it once to start it up...*(um hm)* and you start it (F) and it goes around and around and right at the point of where the driver is (G), is a big tank *(right)* for gasoline *(yup)*, the fuel for it...and it goes very fast...oh I don't know how uh many miles an hour *(fast)*...very fast, 'cause (G) the policemen have to use it uh...you want to know...how they use it (G)? to chase speeders...*(right, very good)*...and they (G) also have it the other way (G)...*(what do you mean, the other way)*...for in races (G) *(oh, in races, yes in races, they use it in races)*...yeah...'cause I know

(F)...'cause (G) my father used to ride one at one time...and he stopped himself (G) because the doctor told him not to (G).

Patient G.T., motorcycle

...motorcycle, yes, I've rode them (G) many times..., [laughing]...PAUSE...(imagine I don't know what it is...explain a motorcycle to me.)...motorcycle is like a large bicycle... (uh huh)...that has a motor in it and you ride it just like you do...an...automobile...(umhmm)...gasoline...(ok)...and it's big...PAUSE...(ok, what else?)...very powerful...(uh huh...what else about it?)...you need a driver's license to drive it...(what else is important about it?)...gasoline, the oil...PAUSE...(uh huh...what's the cool thing about a motorcycle?)...cool thing?(uh huh)...well you ride it...you have to sit on top of it and you ride out in the open...and just have nothin' to protect you...(that sounds right...I've never ridden one)...[laughs]...like a horse...(that's what people say)...yeah...you haven't ridden one?(uh uh)...never ridden on a motorcycle?...I have plenty of times...they're a lot of fun...there are different kinds too...(right...what do you mean, different kinds?)...well, you have the motorcycle you just ride out down the streets...you know...driving and all that...you know...and a sport motorcycle...(right...that's important.)...you go out to the mountains and stuff with it...and then racing motorcycles...(right) different kinds...(good).

Control 4, motorcycle

Motorcycle...I used to own motorcycles...in fact, I used to buy them and sell them...motorcycles...ah...similar to a bicycle, 2 wheels...engine, between, or...within the frame...from, ah 10 horsepower on up to uh...about 70, 60 horsepower...uh...chain, most of them used to have chain drive between the uh transmission and the rear wheel...right, right hand on most Harley Davidsons controlled your gas, the left was your advance and retard, your, your spark...one headlight forward, one taillight in the rear...uh...used to have a sailseat or a pinion seat, or a kingsize seat for carrying an extra passenger...most gas tanks carried, uh 2 uh (F)...regular gas tank...a gallon and a half, auxiliary approximately a little over a gallon...one quart of oil...one battery, uh...top speed on most bikes back then was about 75 miles per hour...the newest go up to 150 miles...um....

Patient H.M., swan

Well...a swan...flies around sometime (um hmm)...but it goes on the water too (um hmm)...and...goes after fish in a way (G)...(um hmm) and...PAUSE...(what else does it do, what does it

look like)...and it's got a very long neck...(um hmm) and uh...well these (G) is just scooped over a certain area (G) and they (G) find the fish...a lot of fish (F) in there (G) and they could swallow them (G)...(um hmm) and...are...and...(F)...by doin' that (G) just sometimes (G) they can keep them stored in their mouth. (um hmm)...and uh, and the throat (F)...(um hmm)...so (G) they can get everything down that way (G)...(exp what, what is their color)...white...some of them are white, some of them are brown...(ok)...but you mostly think of a white swan...(ok).

Patient G.T., swan

...a swan is a...uh. a large bird who lands on the water...PAUSE...(uh huh, ok...what else?)...swims...(uh huh...what else?)...PAUSE...(what does it look like?)...giant turtle...(what does it look like?)...giant turtle, it's, it's like a turtle...swan...big...it's huge...it's big (F2)...(uh huh, tell me more about what it looks like)...(try to describe it)...umm...well...(what color is it?)...um I dunno...[laughing]...(you're not really sure?...what do you think?)...probably a blackish brown color...(ok...ok).

Control 4, swan

Swan...it's a long neck (G)...like an S curve...basically most are white...uh, big beak...they dive for their fish...uh, when I say dive, they stick their neck way down and they will follow through (G)...they have webbed feet, uh,...very fast swimmers, very graceful...mate for life...uh, they eat most anything, bread, food, seeds, they'll eat that along with smaller fish...um...that's about it...they grow, I'm gonna guess, in weight, they should grow up to about maybe 15 pounds, 10–15 pounds...they're lightweight really, when you get down to it, 'cause all feathers (G)...and they shed water, their...their feathers will not absorb water...and I did say webbed feet....

Acknowledgments

This research was supported by the Medical Research Service of the Department of Veterans Affairs, NIMH grant 24600, the Metropolitan Life Foundation, DFG grant Vo 770/1-1 (to H.S.), and a Howard Hughes Medical Institute Predoctoral Fellowship (to E.A.K.) We thank Lisa Stefanacci, Joseph Manns, Gary Press, Joyce Zouzounis, Shauna Stark, and Jennifer Frascino for assistance; Michael Ullman for providing the Nouns and Verbs test; and John Hodges for providing tests 1 and 3–8. Heike Schmolck is now at the Department of Neurology, Baylor College of Medicine, Houston, Texas.